

# Hair removal with a second generation broad spectrum intense pulsed light source – a long-term follow-up

Agneta Troilius & Carl Troilius

**Authors:**

**Agneta Troilius MD**  
Department of Dermatology,  
University Hospital, Malmö,  
Sweden

**Carl Troilius MD**  
Plastic Surgery Centre, Malmö,  
Sweden

Received 13 July 1999

Accepted 27 July 1999

**Keywords:**

*bikini lines – hair management – hair removal – intense pulsed light – long-term hair reduction – non-coherent light*

**BACKGROUND:** There is an increasing demand for safe and efficient hair removal. Although long-term hair removal has been demonstrated using lasers and non-coherent light sources, permanent hair removal has been difficult to claim due to the long growth/rest cycle of normal human hair follicles. **OBJECTIVE:** To evaluate bikini line hair removal with a second generation intense pulsed light (IPL) source.

**METHOD:** Ten females (20 bikini lines) with dark hair and skin types II–IV were treated with an IPL (600 nm) four times with a 1-month interval. Counting of the hair follicles was carried out with a computer imaging system before treatment, and 4 and 8 months after the treatments.

**RESULTS:** Hair reduction of 74.7% ( $SD \pm 18.3\%$ ) was seen 4 months after the treatments and 80.2% ( $SD \pm 20.3\%$ ) 8 months after the last treatment. Only minimal side effects were noted and no pain or other discomfort was registered during the treatments.

**CONCLUSION:** The present study demonstrated that this new IPL system is both efficient and safe for hair removal. Because the follow up period of 8 months is twice the cycle time for hairs in the bikini line area, the obtained hair reduction in this study was long-lasting.

*J Cutan Laser Ther* 1999; 1: 173–178

## Introduction

Many people either desire more hair or want to get rid of unwanted hair. Traditional methods of hair removal such as shaving, plucking, waxing and electrolysis are

associated with clinical limitations and side effects. Hair removal using optical methods was discovered as early as 1979<sup>1,2</sup> and since 1995 the public and manufacturers have shown a great interest in the new hair removal lasers and intense pulsed light (IPL) sources that have been developed. Unfortunately, clinical studies regarding the long-term efficacy and clinical safety of these procedures have lagged behind the actual widespread use of this modality all over the world.

Long-term or permanent hair reduction is based on

Correspondence: Agneta Troilius, MD, Department of Dermatology, University Hospital, S-205 02 Malmö, Sweden. Tel: +46 (0)40 33 17 00; Mobile: +46 (0)70 5 26 3000; Fax: +46 (0)40 33 70 13; E-mail: agneta.troilius@derm.mas.lu.se

thermal damage to the hair follicle obtained by absorption of optical energy in the hair followed by heat conduction to the surrounding hair follicle cells. This damage may be restricted to the hair follicles by the principle of selective photothermolysis,<sup>3</sup> which predicts that thermal injury will be restricted to a hair follicle if the pulse duration is shorter than the cooling time or thermal relaxation time of the follicle. Melanin in the hair shaft, the bulb and parts of the outer root sheath is the main chromophore and broadly absorbs light across the optical spectrum.

Treatment with different lasers, for example ruby,<sup>4-7</sup> alexandrite,<sup>8,9</sup> Q-switched Nd:YAG<sup>10-12</sup> and diode lasers, as well as broadband light, have proved to delay hair growth significantly.<sup>13-15</sup> However, it has been difficult to compare the devices in terms of the long-term or permanent hair removal result because the follow-up periods in some studies have been too short, which means that the full growth cycle as well as the recovery time for the hair follicles have not been covered. Also confusing is that many studies have included different anatomical locations with different growth cycles in the same study. Evaluation of the abilities of the different devices for hair reduction may be inaccurate unless exact hair follicle counting is provided. A computer imaging system (CIS) was used for this purpose in the present study. Furthermore, the different devices all have different pulse durations, wavelengths, beam profiles and fluences.

In order to evaluate the long-term hair reduction potential of this new IPL device, a follow-up time of at least two full hair cycles was chosen. This was obtained in 8 months for hairs in the bikini line area (Richards-Meharg table).

## Materials and methods

### Volunteers

A total of 11 healthy females, without any hormonal disturbances and with a mean age of 31 (SD  $\pm$  9.2) years (range 21–56) were treated on both sides of their bikini areas.

All volunteers had dark blond hair to dark hair with Fitzpatrick skin types II–IV, with the majority being type III. The tan of the treated areas varied between none to heavy; the majority were evaluated to have a medium pigmentation.

### The IPL system

The Ellipse Relax Light 1000 (Danish Dermatologic Development, Hoersholm, Denmark) is a second generation IPL system device designed for long-term epilation and vascular treatments, and the mode of action is based on the theory of selective photothermolysis.<sup>3</sup>

In this present study, a handpiece for hair removal with a special 'dual mode filtering' was used. It consists of a high-energy flashlamp and a fixed and sealed 600-nm filter together with a water-filled filter reducing wavelengths above 950 nm. In this way the water-filled filter absorbs all wavelengths that would otherwise lead to skin burns due to non-specific heating of the water content of the epidermis. This integrated water filtering enlarges the therapeutic window and there is therefore no need for changing filters according to skin type and pigmentation. The large spot size of 48  $\times$  10 mm increases the effective optical depth in the skin tissue. The direct contact between the light guiding crystal and the skin is accomplished by a thin layer of optical index-matching gel, and the design of the light guide allows re-use of reflected and scattered photons by reflecting them back into the skin (photon recycling) (Figure 1).

### Treatment procedure

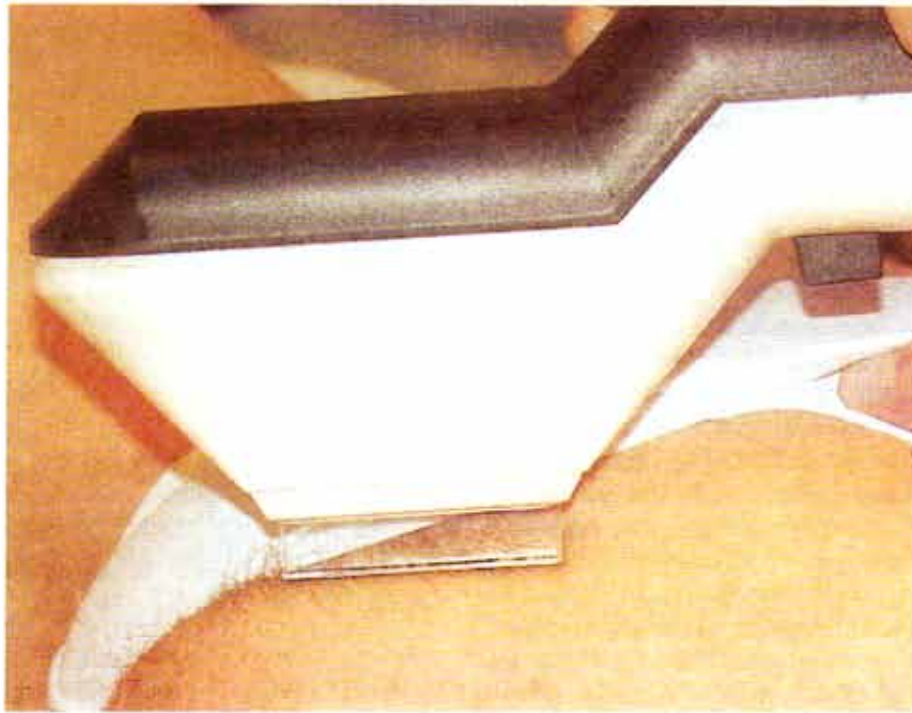
Prior to the treatment, the groin area was photographed and shaved. A transparent optical index-matching gel was applied to the skin. The test areas were treated in one pass with an overlapping of 10%. No cooling or any other post-treatment regime was utilized.

Four treatments were performed on each volunteer on both sides of the bikini areas with intervals of 4–5 weeks.

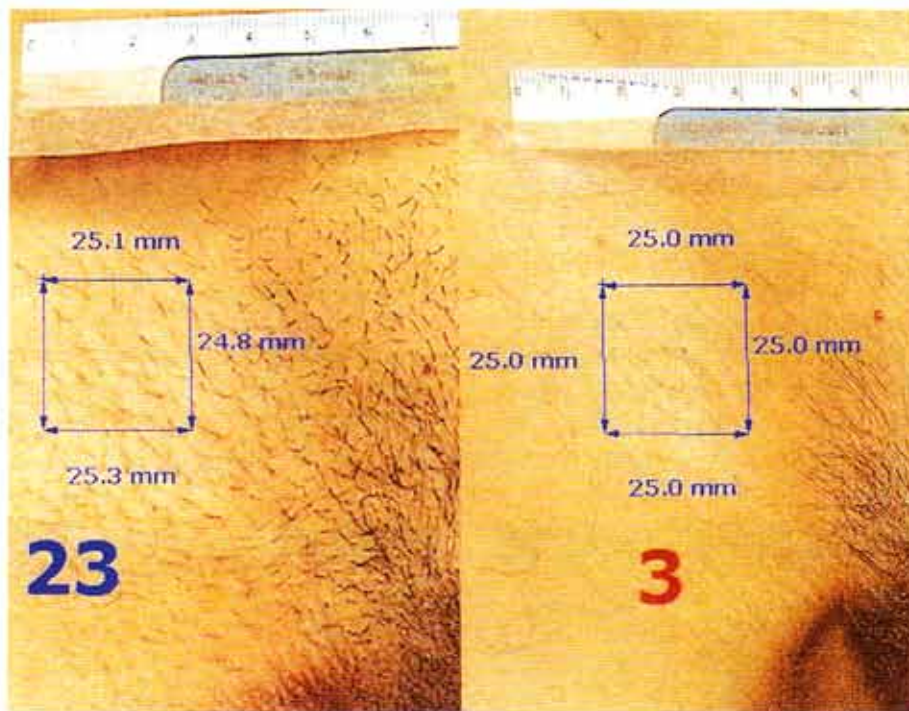
During the treatment the handpiece was held with a moderate pressure on the skin in order to empty the cutaneous blood vessels. This also results in indentations in the gel layer where the treatments have been performed. No alignment sheets were needed.

The thermal relaxation time of the relatively thick hairs of the bikini area is in the range of 30–50 ms. The IPL can be adjusted to a pulse duration up to 50 ms. For all volunteers, a pulse duration of 44.5 ms was chosen. The pulses were composed of an undulating train of four individual pulses of 10 ms spaced by 1.5-ms intervals. The fluences used were a mean of 18.3 (SD  $\pm$  3.3) J/cm<sup>2</sup>.

The follow-up visits included digital photography 4 and 8 months after the last treatment (Figure 2). Two of the 11 patients were controlled 10 months after the treatments and their treatment results improved in comparison with their hair reduction at the 4-month control. Photographs were stored and analysed on a computer system (Mirror Image Software System; Canfield Clinical Systems, Fairfield, NJ, USA). A standardized photography set-up was used with the photographs centred in the groin area and with the volunteers' legs abducted 60° in order to get the identical skin tension in the groin area at each visit. When comparing the photographs, compensations for different focal distances during exposures were performed. Each photograph was calibrated to a standard size in the computer using a ruler, and test areas of 25  $\times$  25 mm were marked for hair counting. When comparing pictures on the same volunteer, the target area was mapped on the pretreatment picture and all subsequent



**Figure 1**  
The use of the IPL system handpiece is demonstrated on the skin.



**Figure 2**  
Bikini line before (left panel) and 8 months after (right panel) four IPL treatments, demonstrating how the follicles were counted with the help of the computer imaging system.

photographs on the same volunteer were measured in the same area of each photograph.

Computerized photographs like these can be enlarged and brightened, which facilitates the counting of separate strands of hair in the test areas.

## Results

Before treatment, the average number of hairs in the target areas of 25 × 25 mm was 33.9 (SD ± 9.4). At the first follow-up, 4 months after the last treatment, 20 analysed treatment sites demonstrated a reduction of the average number of hairs by 74.7% (SD ± 18.3%).

At 8 months following the last treatment an average hair reduction of 80.2% (SD ± 20.3%) was registered (Table 1). The individual results for each volunteer are demonstrated in Table 2. The distribution of the results after grouping the results in poor (0–24%), moderate (25–49%), good (50–74%) and excellent (75–100%) are shown in Table 3.

Some 70% of the volunteers experienced excellent (75–100%) hair reduction. There was no statistically significant difference between the result obtained at the 4-month and the 8-month follow-up, which may indicate that the hair reduction obtained may be permanent.

Two of the volunteers also suffered from folliculitis caused by ingrowing hair due to shaving; however, after the first treatment both of them experienced complete improvement. After the treatments all volunteers experienced a smoother texture of the skin and the quality of the remaining hairs had changed from a darker course type to a lighter thinner type of hair. Volunteers with thicker hair had a slower response than those with thinner hair.

## Side effects

No major immediate or late complications were seen after the treatments. Most volunteers experienced a light redness as well as slight tenderness of the treated area, which disappeared within 2 days.

After the second treatment two volunteers developed a few small blisters as a result of shaved burned hair debris attaching to the front surface of the light guide crystal. Both volunteers healed within a week without any scarring. No patients experienced any pigment changes

Hair reduction	4-Month follow-up (%)	8-Month follow-up (%)
Minimum	42.4	42.9
Maximum	100.0	100.5
Average	74.7	80.2
Standard deviation	18.3	20.3

**Table 1**

Hair reduction – showing the minimum and maximum as well as the average result after 4 and 8 months.

Bikini lines	4-Month follow-up (%)			8-Month follow-up (%)		
	Before	After	Reduction	Before	After	Reduction
1 left	33	19	42.4	33	6	81.8
2 left	50	11	78.0	50	17	66.0
3 left	21	1	95.2	25	0	100.0
4 left	37	19	48.6	37	17	54.1
5 left	25	5	80.0	25	0	100.0
6 left	30	9	70.0	30	6	80.0
7 left	34	15	55.9	34	19	44.1
8 left	48	18	62.5	48	12	75.0
9 left	30	6	80.0	30	3	90.0
10 left	29	0	100.0	29	1	96.6
1 right	45	20	55.6	45	3	93.3
2 right	55	8	85.5	55	16	70.9
3 right	31	3	90.3	31	0	100.0
4 right	40	13	67.5	40	23	42.5
5 right	20	0	100.0	20	0	100.0
6 right	29	4	86.2	29	4	86.2
7 right	28	15	46.4	28	16	42.9
8 right	33	9	72.7	33	3	90.9
9 right	30	7	76.7	30	2	93.3
10 right	30	0	100.0	30	1	96.7

Before and after measurements represent the number of hairs in the 25 × 25 mm target area.

**Table 2**

Individual hair reduction of the 20 treatment sites after 4 and 8 months.

after the treatments.

Patients were asked to grade the discomfort or pain associated with the treatment on a visual analogue scale of 1–10, where 0 was defined as no pain or discomfort and 10 was maximally imaginable pain. The average pain score was 5 on the medial areas and 3 on the lateral areas.

## Statistics

The Wilcoxon's test for paired differences was used;  $p < 0.05$  was considered as the level of significance.

## Discussion

To our knowledge this is the first study published using a second generation IPL. The present study demonstrates a very high percentage of hair reduction after more than two full hair follicle cycles in the bikini area without any

Hair reduction (%)	4-Month follow-up (%)	8-Month follow-up (%)
0–25	0.0	0.0
25–50	15.0	15.0
50–75	30.0	15.0
75–100	55.0	70.0

**Table 3**

The distribution of hair reduction results at 4 and 8 months after dividing into four groups.

significant side effects. These results may be due to the very long light pulses, which match the thermal relaxation times of the relatively coarse hairs in the bikini area. Despite the follow-up of more than two full hair cycles, it is not known whether these results are permanent. Hillock and Ackerman<sup>16</sup> stated that the destruction of the hair papilla is essential for permanent epilation, although Oliver<sup>17</sup> and Costarelis et al<sup>18</sup> have claimed that hair follicles can regenerate in the absence of the hair bulb. Histology has shown miniaturization and granulomatous degeneration of the hair follicles after normal-mode ruby laser treatment with less effect on blond hair and a fluence-dependent hair reduction.<sup>7</sup> On the other hand, McCoy et al<sup>19</sup> found that there was no evidence of permanent follicle death after one 3-ms pulsed ruby laser treatment. Also, the papillae always remained viable. New anagen follicles were still evident after three treatments, but there were no hairs extending to or through the epidermis. They concluded that it is possible that laser-induced damage to the isthmus and upper stem may interfere with the interaction between dermal and epidermal germinative cells, thus inhibiting or altering the normal hair cycle.

Whether the hairs are in anagen or telogen phase at the time of the treatment may be important for optical depilation because only anagen hairs are particularly sensitive to chemical, cytostatic, physical, hormonal, infectious or inflammatory insults.<sup>20</sup> It is not known if this also applies to the damage caused by lasers and IPL sources. Due to unsynchronized cyclic growth, not all hair follicles will be in anagen phase<sup>21-24</sup> at the time of the treatment. More treatments will therefore always be required in the same area to ensure treatment of all follicles while in anagen phase. Maybe the best treatment interval should be when a certain amount of the hair has come back instead of having fixed intervals. Shaving does not affect the rate or duration of the anagen phase or diameter of human hair,<sup>25</sup> but it may trigger a switch from synchronous telogen to anagen.<sup>26</sup> Therefore, the patients should be instructed to shave the hairs a few days before treatment.

Only minimal side effects were registered in this study. This might be attributed to the large 'therapeutic window' obtained by the dual filtering of the flashlamp light. The light filtering reduces the amount of non-

specific absorption in components of the skin other than hair follicles. Also, no epidermal cooling was used. The transparent gel was applied only in a thin layer as an optical coupling medium. After treatment no cool packs or cold gauzes were applied unless the patient developed erythema or wheals – which was a rare incidence during this study.

In clinical practice, pulse width and fluence should be adjusted according to skin type and pigmentation. In the study of Hasan et al,<sup>27</sup> one patient developed multiple postinflammatory hyperpigmented macules on her thighs due to sun exposure after treatment of unwanted hair using a normal-mode ruby laser. Avoidance of exposure to ultraviolet light before and several months after treatment should be emphasized to all patients prior to therapy.

To date, not many comparative studies have been published. Lask et al made a comparative evaluation of the ruby, alexandrite and another broadband IPL system, and found them all to be efficient and safe with proper patient selection.<sup>14</sup> There is an ongoing almost overwhelming development of lasers and IPL systems and it is often hard to obtain 'up-to-date' information. Therefore, it may be difficult for the clinician in this expanding market to choose the best system. These devices still have the potential to cause injury when used improperly and the recommendation is to follow precise treatment guidelines in order to attain optimal results.

Standardization of treatment parameters for long-term or permanent hair removal and comparative trials of different hair removal methods are welcomed. Olsen<sup>28</sup> suggests that such hair studies should be performed in non-androgen-dependent areas in women and that the post-treatment period ideally should include one complete hair cycle for that body area plus an additional 6-month 'recovery' time. This regime was followed in the present study suggesting that the presented data may be – if not permanent – then at least valid for a very long time.

### Acknowledgement

The authors would like to thank Lena Olsson, RN, for help with administration and treatments.

## References

1. Clement M. Depilation by ruby laser. PCT patent application GB94/02682.
2. Zaias N. Method of hair depilation. U.S. Patent 1991; 192: 0,0059.
3. Andersson RR, Parrish JA. Selective photothermolysis: precise microsurgery by selective absorption of pulsed radiation. *Science* 1983; 220: 524–7.
4. Grossman MC, Dierickx C, Farinelli W, et al. Damage to hair follicles by normal-mode ruby laser pulses. *J Am Acad Dermatol* 1996; 35: 889–94.
5. Lask G, Elman M, Slatkine M, et al. Laser-assisted hair removal by selective photothermolysis. Preliminary results. *Dermatol Surg* 1997; 23: 737–9.
6. Bjerring P, Zachariae H, Lybecker H, et al. Evaluation of the free-running ruby laser for hair removal. A retrospective study. *Acta Derm Venereol* 1998; 78: 48–51.
7. Dierickx CC, Grossman MC, Farinelli WA, et al. Permanent hair removal by normal-mode ruby laser. *Arch Dermatol* 1998; 134: 837–42.
8. Finkel B, Eliezri YD, Waldman A, et al. Pulsed alexandrite

- laser technology for non-invasive hair removal. *J Clin Laser Med Surg* 1997; **15**: 225-9.
9. Boss WK Jr, Usal H, Thompson RC, et al. A comparison of the long-pulse and short-pulse Alexandrite laser hair removal systems. *Ann Plast Surg* 1999; **42**: 381-4.
  10. Goldberg DJ, Littler CM, Wheeland RG. Topical suspension-assisted Q-switched Nd:YAG laser hair removal. *Dermatol Surg* 1997; **23**: 741-5.
  11. Nanni CA, Alster TS. Optimising treatment parameters for hair removal using a topical carbon-based solution and 1064-nm Q-switched neodymium:YAG laser energy. *Arch Dermatol* 1997; **133**: 1546-9.
  12. Bencini PL, Luci A, Galimberti M, et al. Long-term epilation with long-pulsed neodymium:YAG laser. *Dermatol Surg* 1999; **25**: 175-8.
  13. Gold MH, Bell MV, Foster TD, et al. Long term epilation using the Epilight broad band, intense pulsed light hair removal system. *Dermatol Surg* 1997; **24**: 128-32.
  14. Lask G, Eckhouse S, Slatkine M, et al. The role of laser and intense light sources in photo-epilation: a comparative evaluation. *J Cutan Laser Ther* 1999; **1**: 3-13.
  15. Weiss RA, Weiss MA, Marwaha S, et al. Hair removal with a non-coherent filtered flashlamp intense pulsed light source. *Lasers Surg Med* 1999; **24**: 128-32.
  16. Holecek BU, Ackerman AB. Bulge-activation hypothesis: is it valid? *Am J Dermatol* 1993; **15**: 235-57.
  17. Olivier RF. The experimental induction of whisker growth in the hooded rat by implantation of dermal papillae. *J Embryol Exp Morph* 1967; **18**: 46-51.
  18. Costasarelis G, Sun TT, Lavker RM. Label retaining cells reside in the bulge area of pilosebaceous unit: implications for follicular stem cells, hair cycle, and the skin carcinogenesis. *Cell* 1990; **61**: 1321-7.
  19. McCoy S, Evans A, James C. Histological study of hair follicles treated with a 3-msec pulsed ruby laser. *Lasers Surg Med* 1999; **24**: 142-50.
  20. Braun-Falco O, Heiligemeier GP. The trichogram, structural and functional basis, performance and interpretation. *Semin Dermatol* 1985; **4**: 40-52.
  21. Kligman AM. The human hair cycle. *J Invest Dermatol* 1995; **33**: 307-16.
  22. Straile WF, Chase HB, Arsenault C. Growth and differentiation of hair follicles between periods of activity and quiescence. *J Exp Zool* 1961; **148**: 205-21.
  23. Sato Y. The hair cycle and its control mechanism. In: Koboti T, Montagna W, eds. *Biology and Disease of the Hair*. Baltimore, MD: University Park Press, 1976: 3-13.
  24. Randall VA, Ebling FJG. Seasonal changes in human hair growth. *Br J Dermatol* 1991; **124**: 146-51.
  25. Oh HS, Smart RC. An estrogen receptor pathway regulates the telogen-anagen hair follicle transition and influences epidermal cell proliferation. *Proc Natl Acad Sci U S A* 1996; **93**: 12552-530.
  26. Trotter M. The resistance of hair to certain supposed growth stimulants. *Arch Derm Syph* 1923; **7**: 93-8.
  27. Hasan AT, Eaglstein W, Pardo RJ. Solar-induced postinflammatory hyperpigmentation after laser hair removal. *Dermatol Surg* 1999; **25**: 113-15.
  28. Olsen E. Methods of hair removal. *J Am Acad Dermatol* 1999; **40**: 143-55.