

Ellipse - I²PL

**Before and After Pictures
Skin Rejuvenation and
Hair Removal**

BEFORE & AFTER ELLIPSE LIGHT

CLINICALLY PROVEN

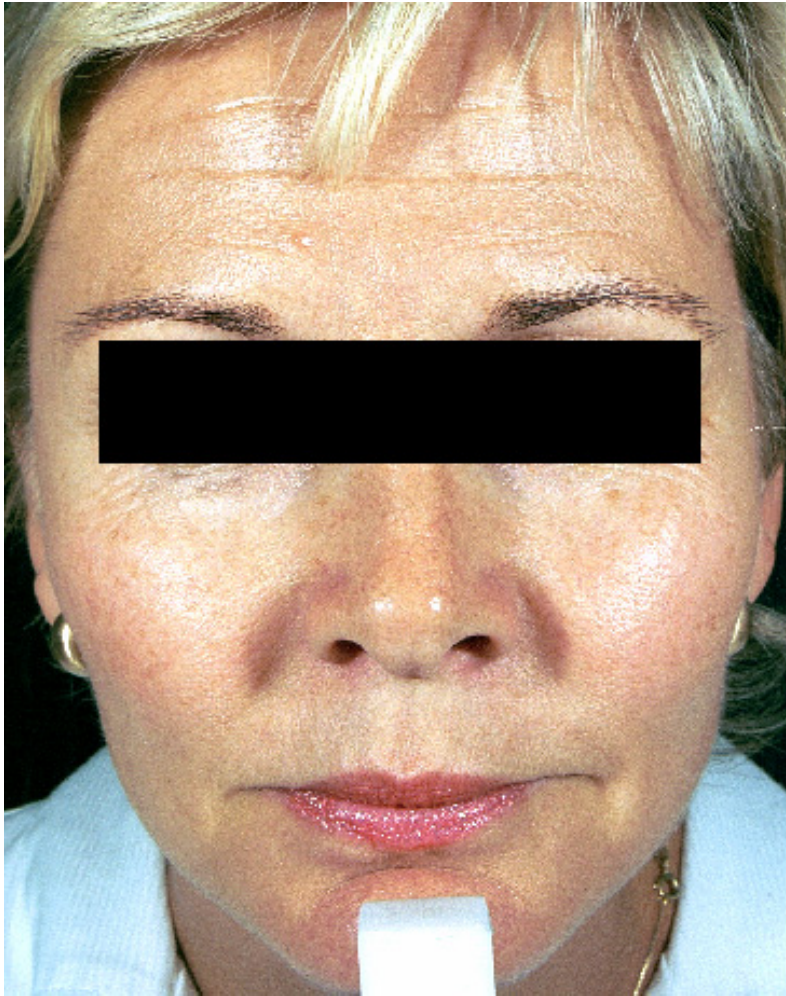SAFE AND EFFECTIVE

Skin Rejuvenation

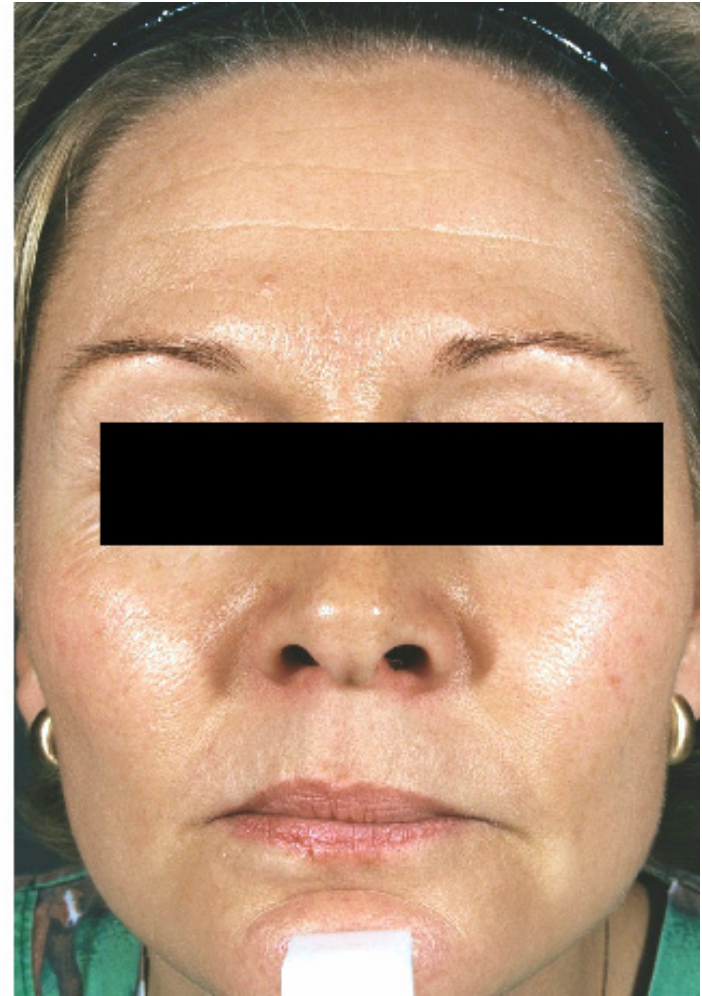BEFORE & AFTER ELLIPSE LIGHT

CLINICALLY PROVEN

SAFE AND EFFECTIVE

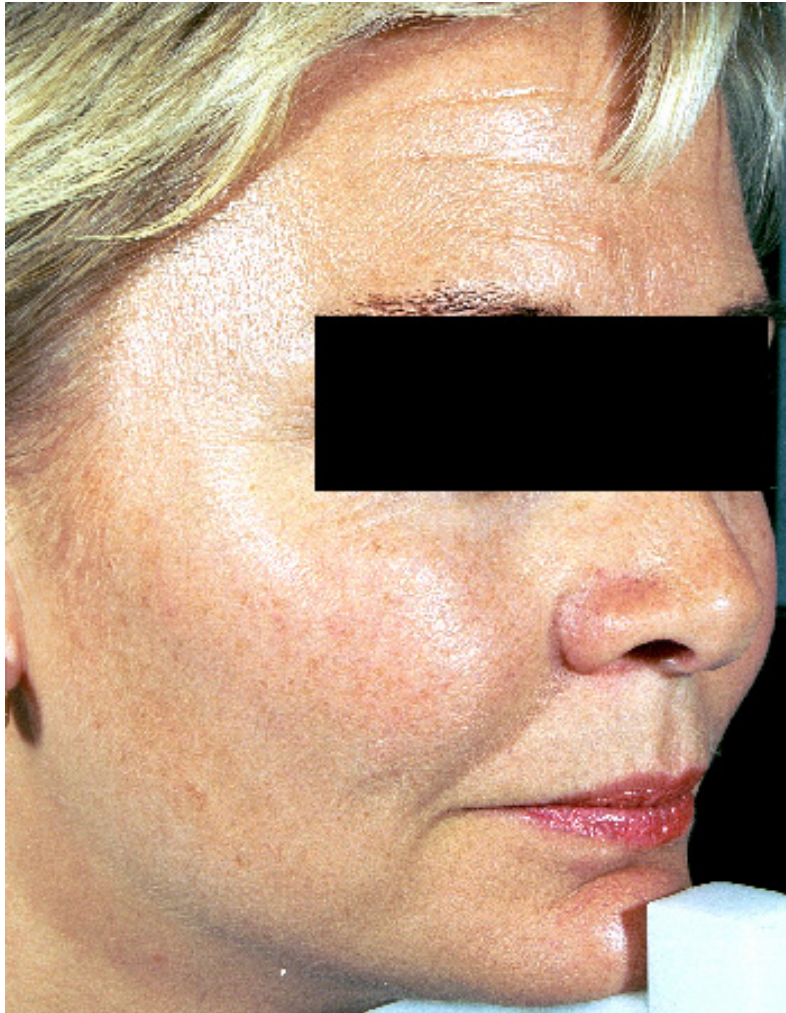

Courtesy of Dr. Agneta Troilius

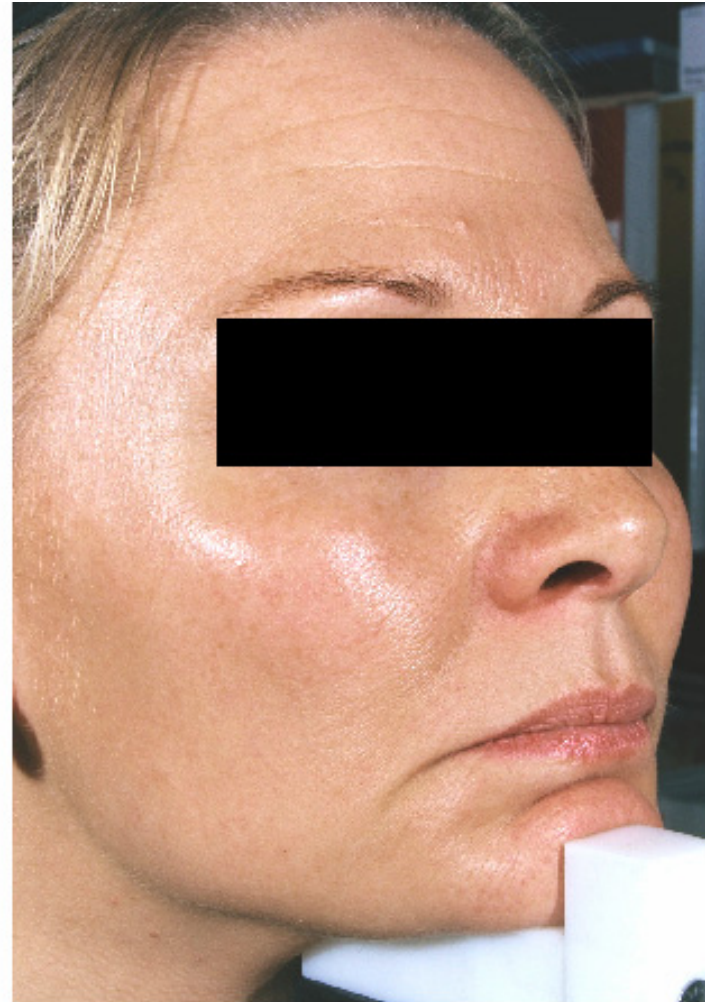

Courtesy of Dr. Agneta Troilius

Before and After 2 Treatments

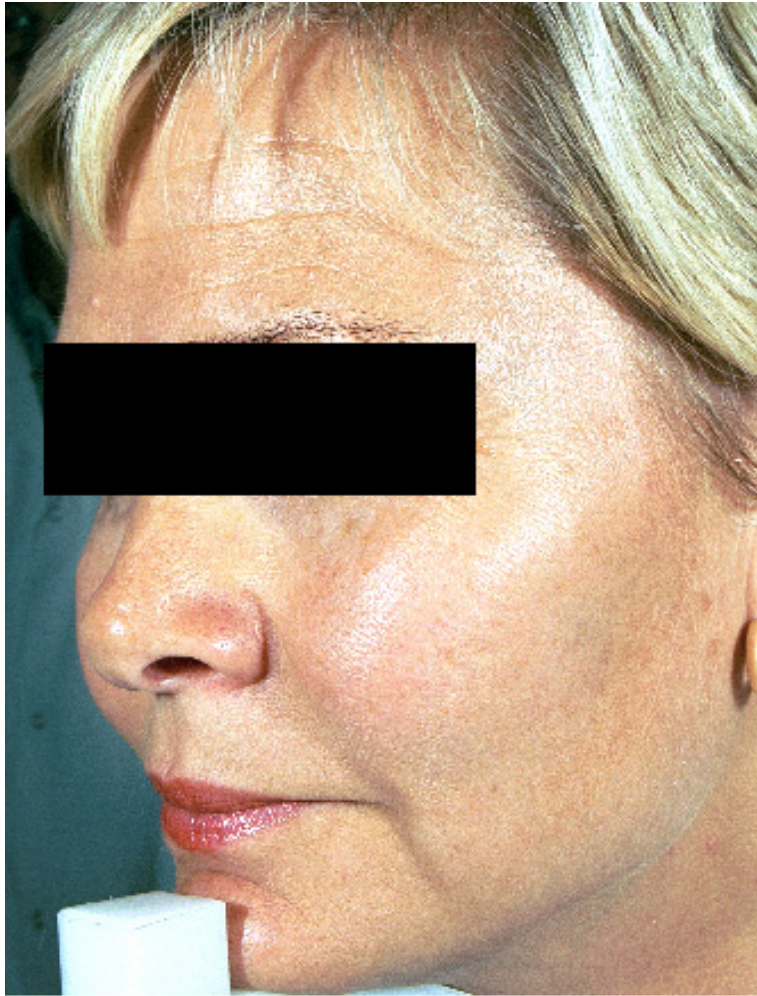

Courtesy of Dr. Agneta Troilius

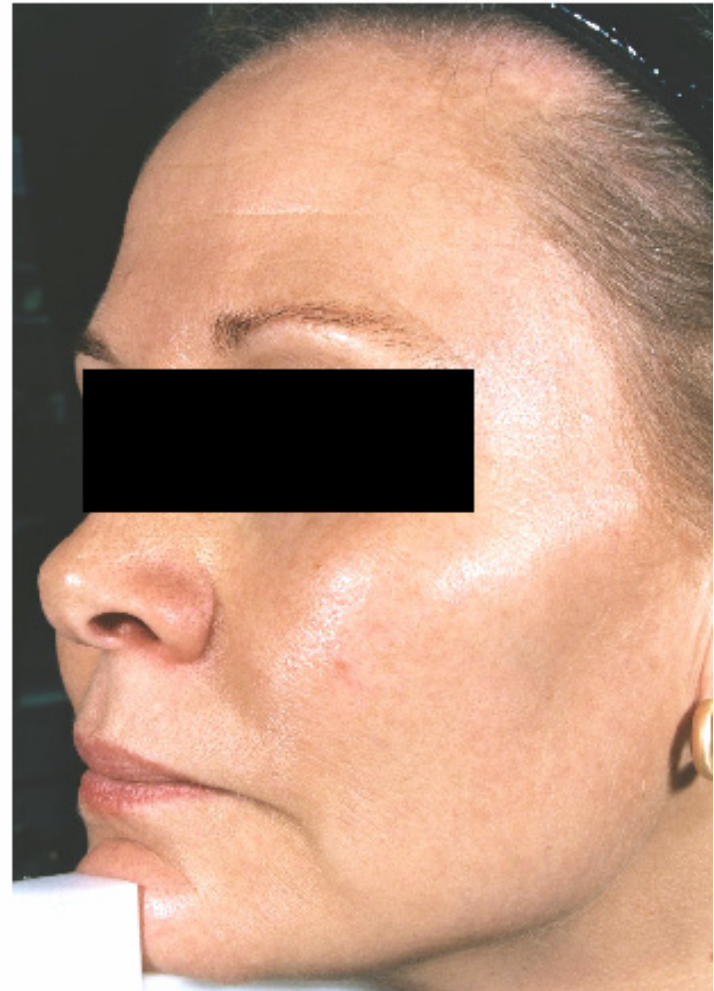

Courtesy of Dr. Agneta Troilius

Before and After 2 Treatments



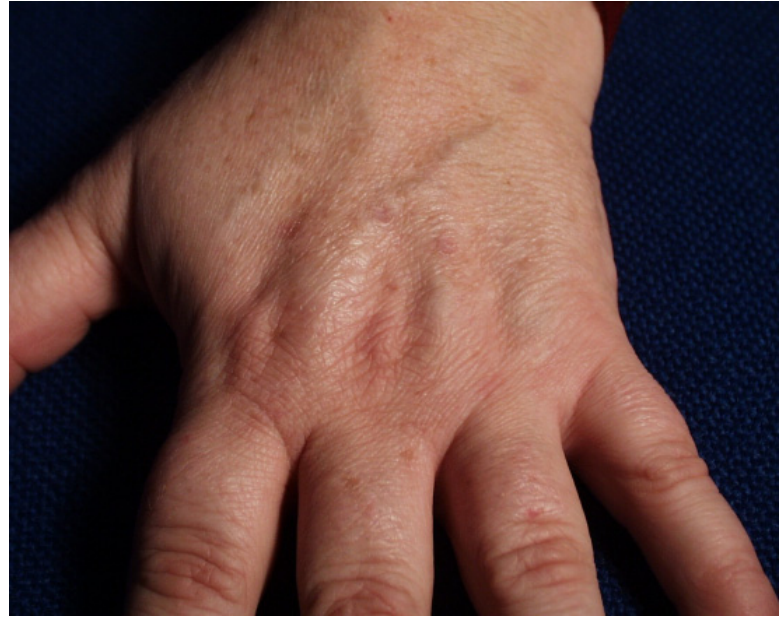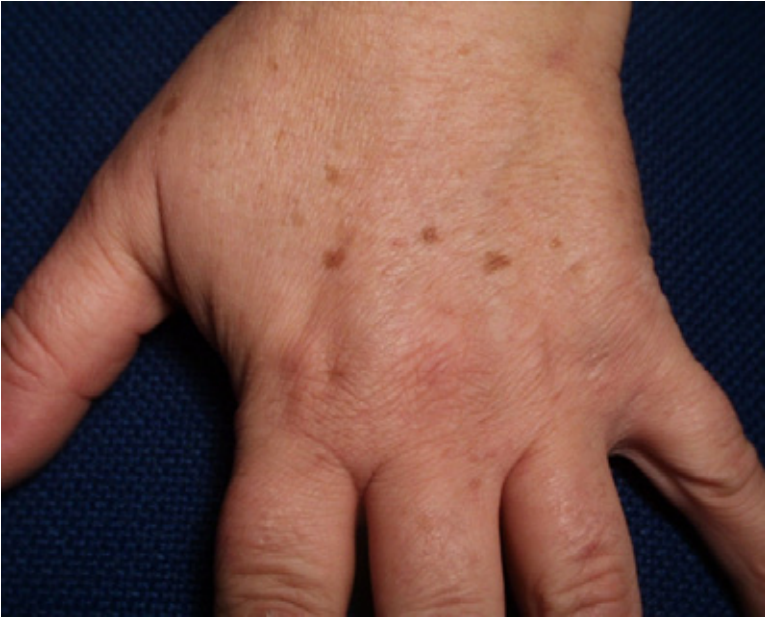Courtesy of Dr. Agneta Troilius



Courtesy of Dr. Agneta Troilius

Before and After 2 Treatments

Solar Lentigo



Female patient before and one month after 1 treatment

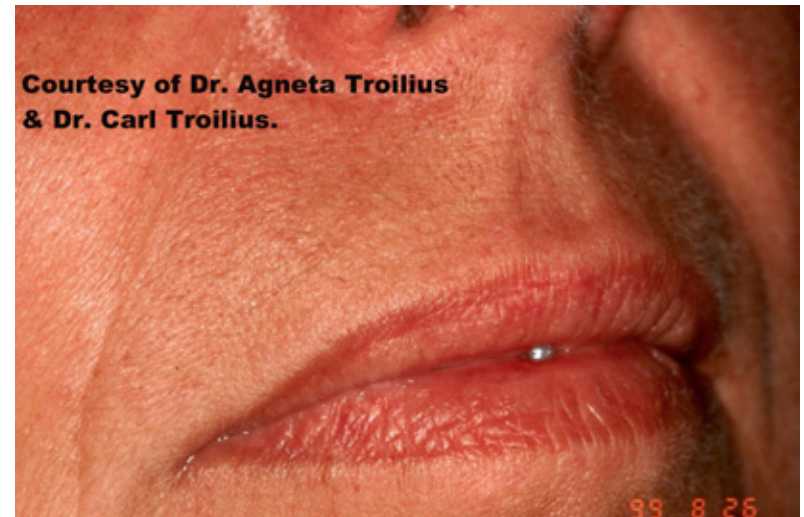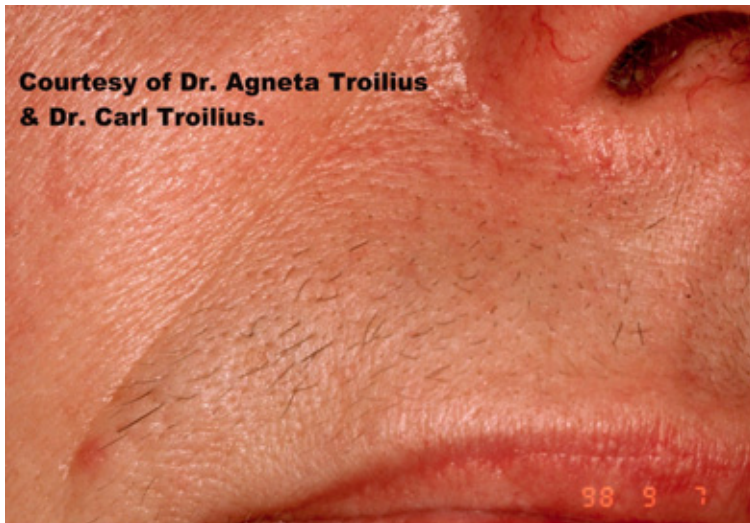
Hair Removal

BEFORE & AFTER ELLIPSE LIGHT

CLINICALLY PROVEN

SAFE AND EFFECTIVE

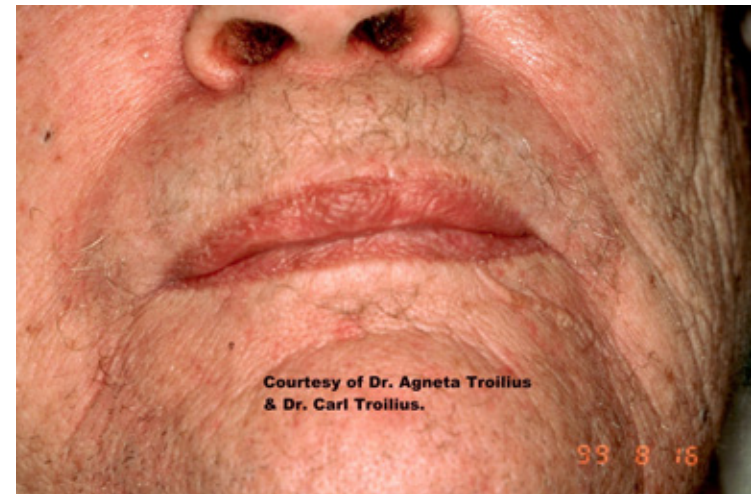
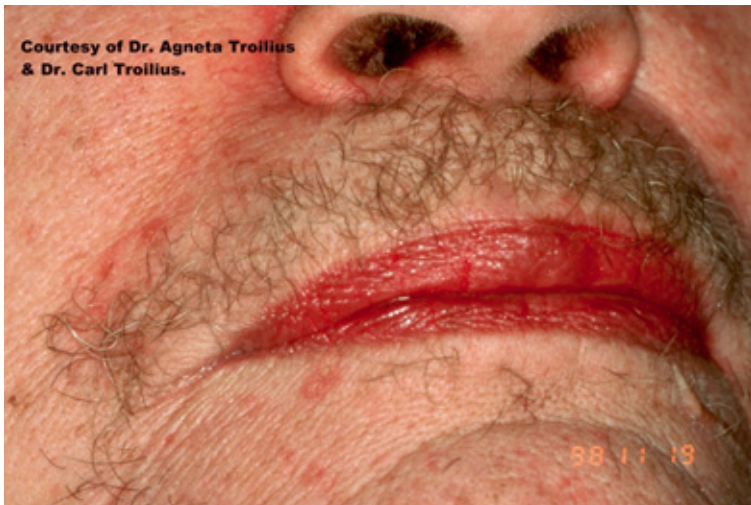Treatment of hair on upper lip on a 30 year old female. The first picture is take prior to the first treatment. The second picture is taken 6 months after the last of 4 treatment.



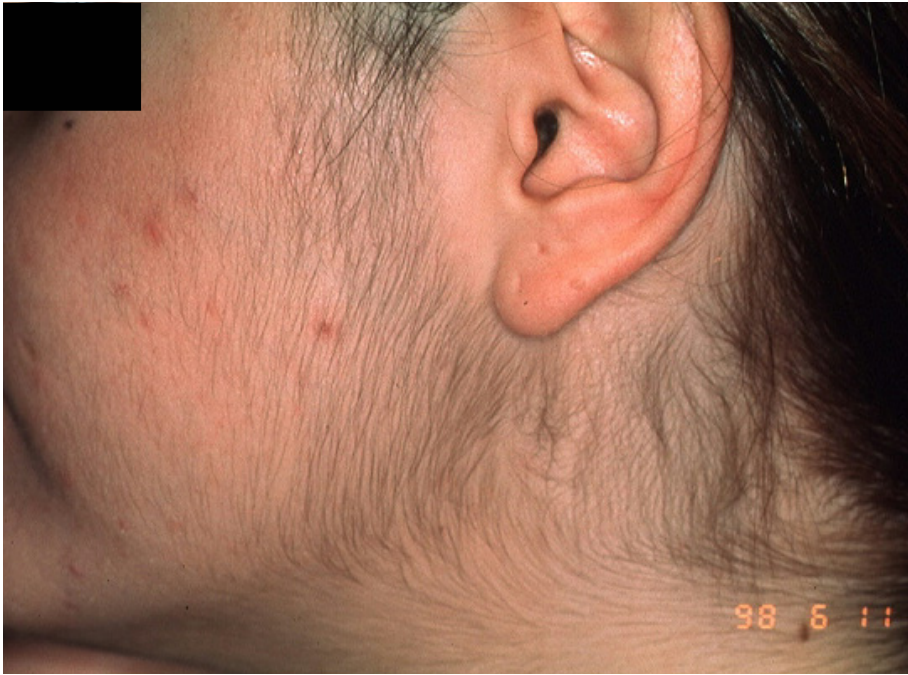Female – 58 years old

After 4 treatments she was so satisfied that she declined from further treatments though they were offered to her free of charge.

The majority of the remaining hairs are white and cannot be treated.

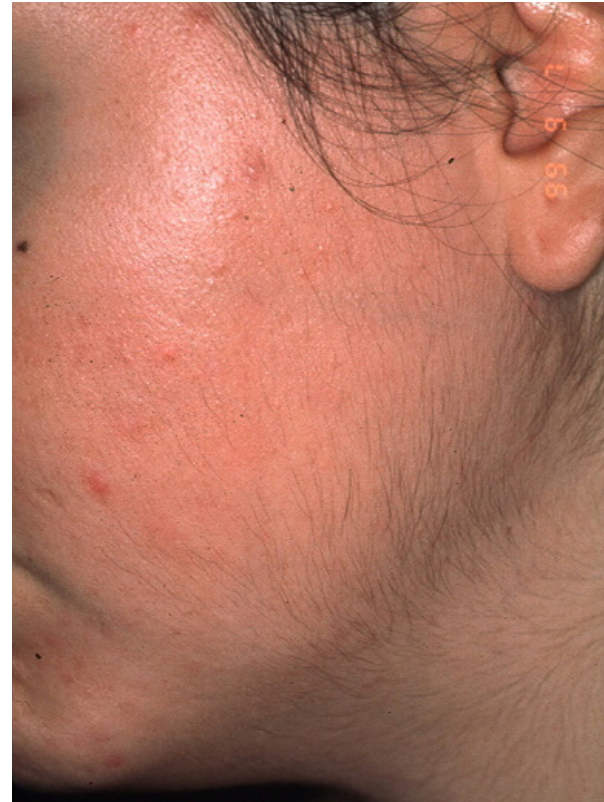

Whiskers



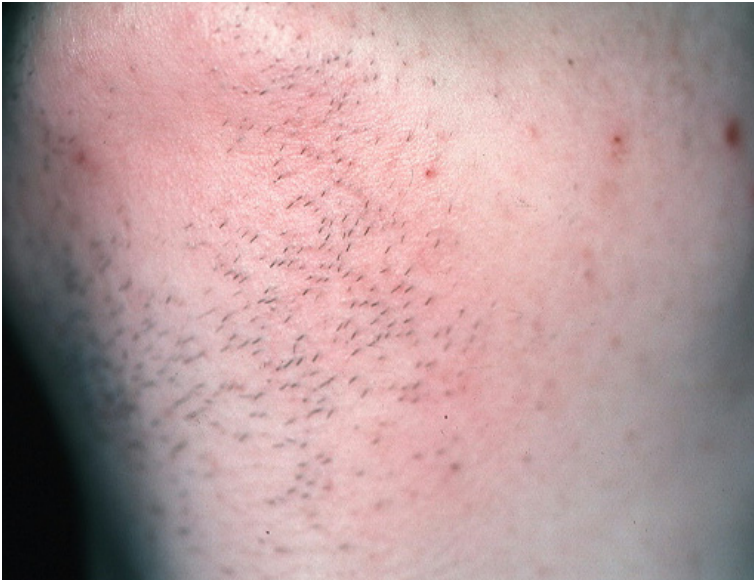Courtesy of Dr. Agneta Troilius

Result after 2 treatments

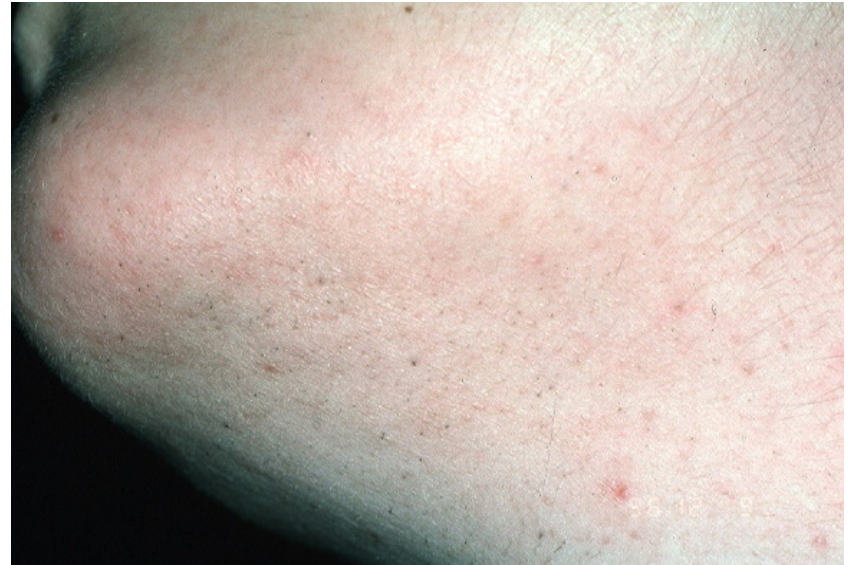

Courtesy of Dr. Agneta Troilius

Chin of a young female



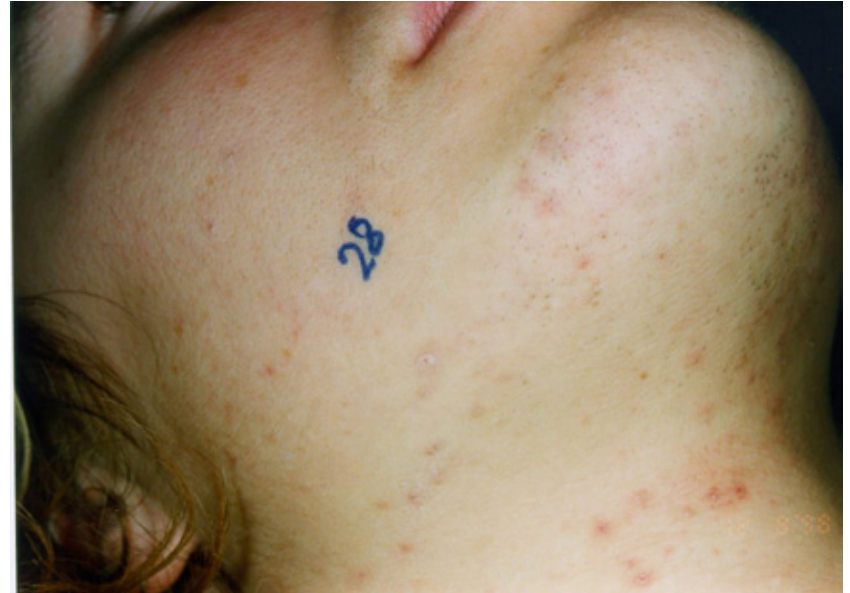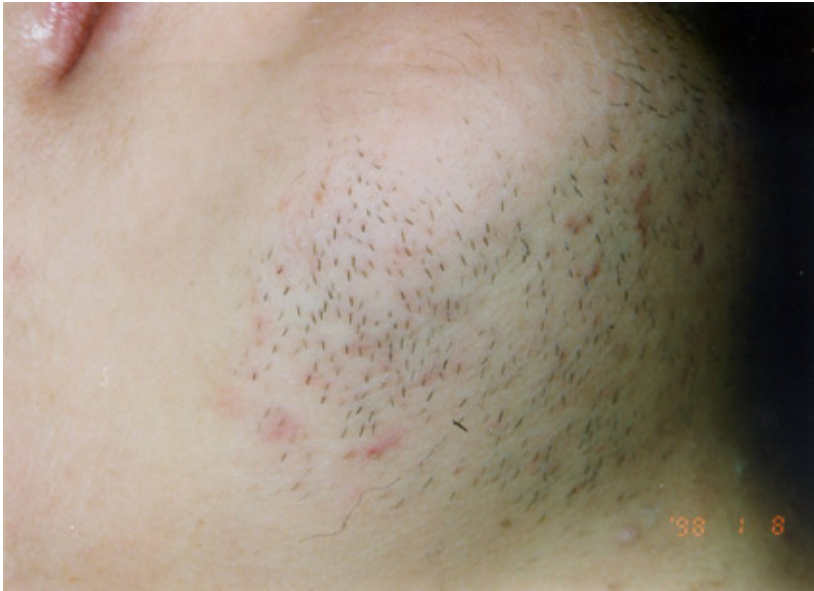Courtesy of Dr. Agneta Troilius



Courtesy of Dr. Agneta Troilius

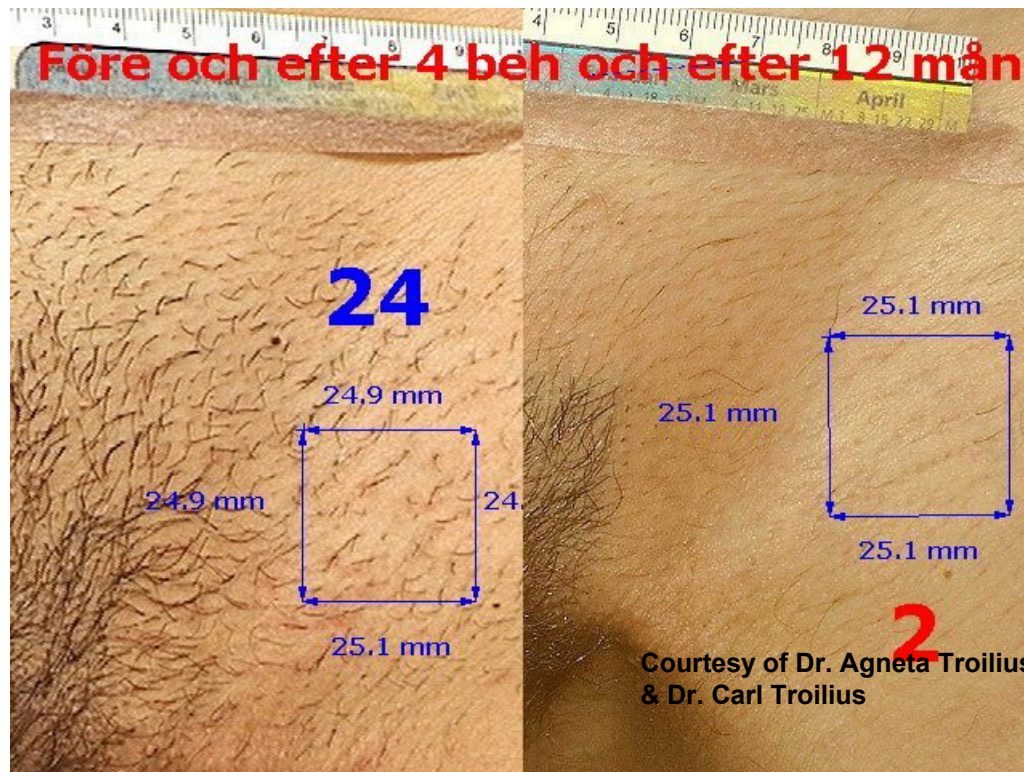Result after 5 treatments

Chin of a young female

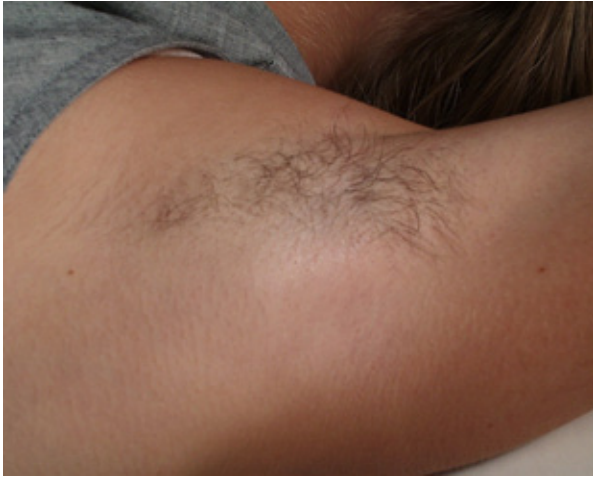

Result after 3 treatments

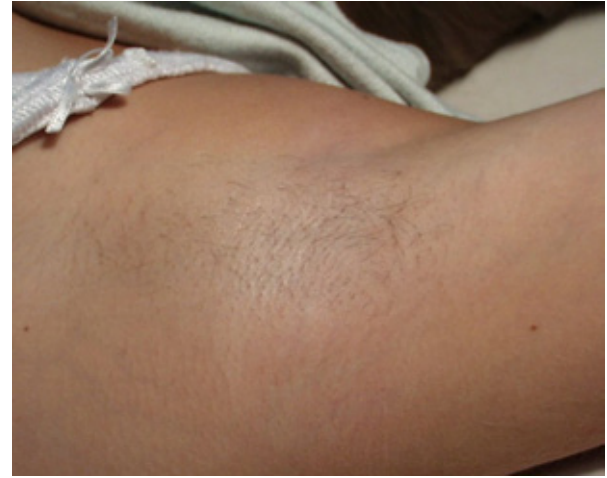Removal of hair in the bikini line.
The first picture is taken prior to the first treatment.
The second picture is taken 12 months after a series of 4 treatments 1 month apart.



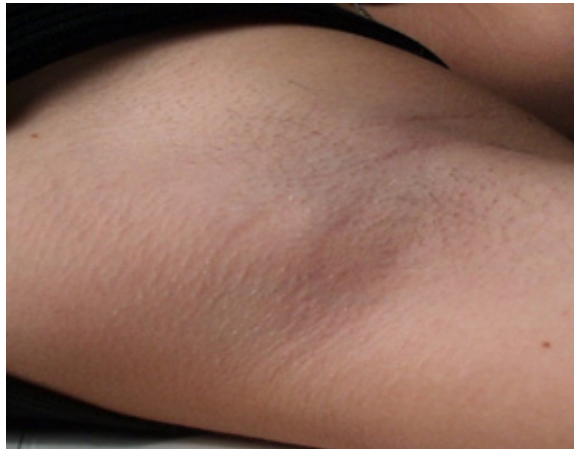Removal of hair in axillae of a young female



Before
treatment

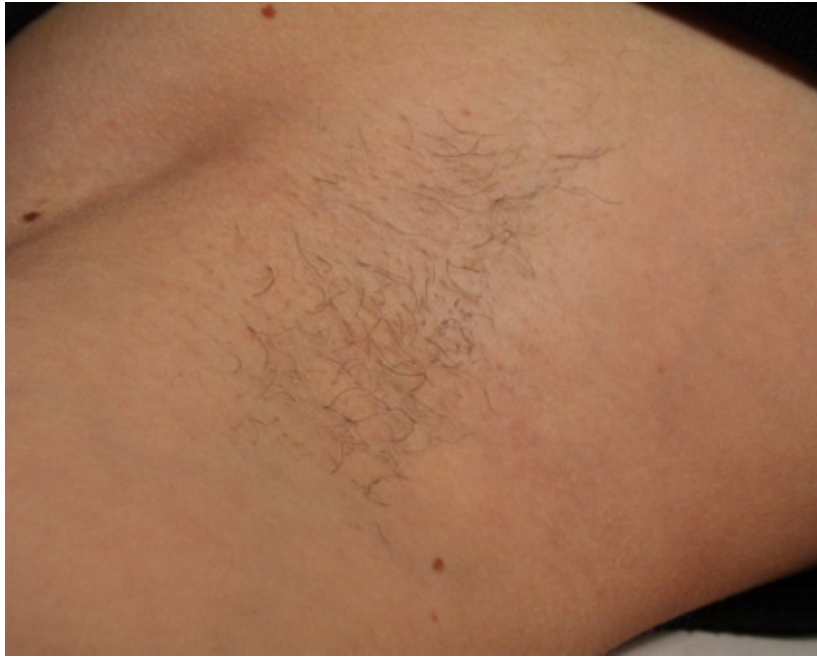

Result after
2 treatments

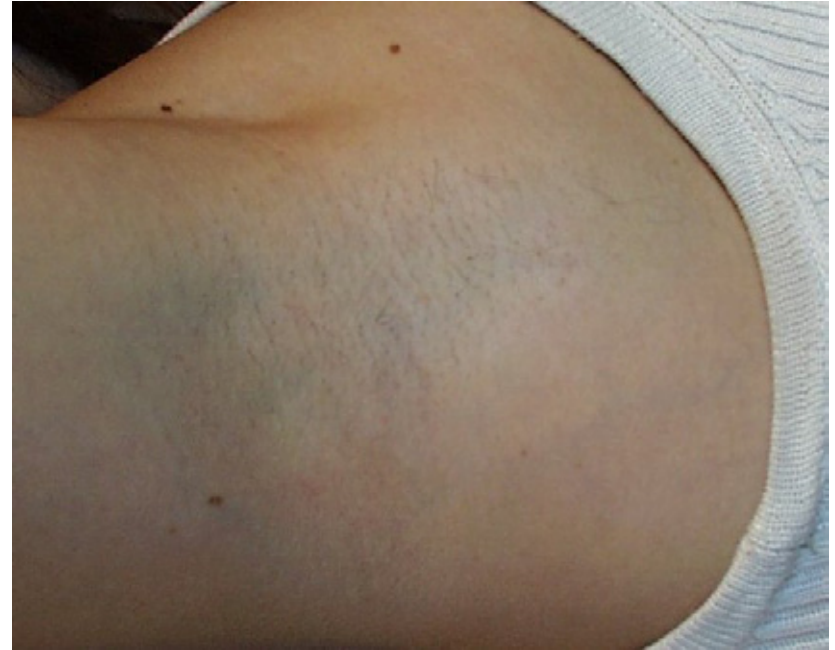

Result after 3 treatments

Removal of hair in axillae of a young female

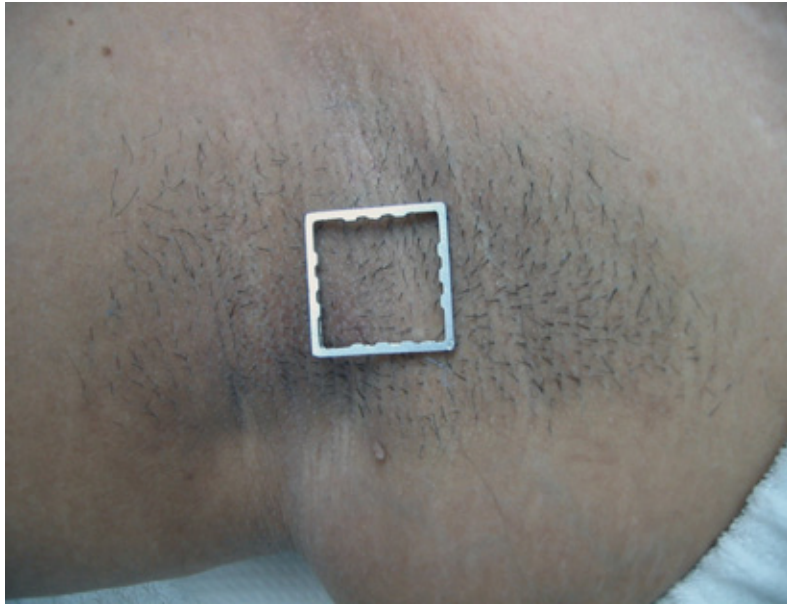


Before treatment



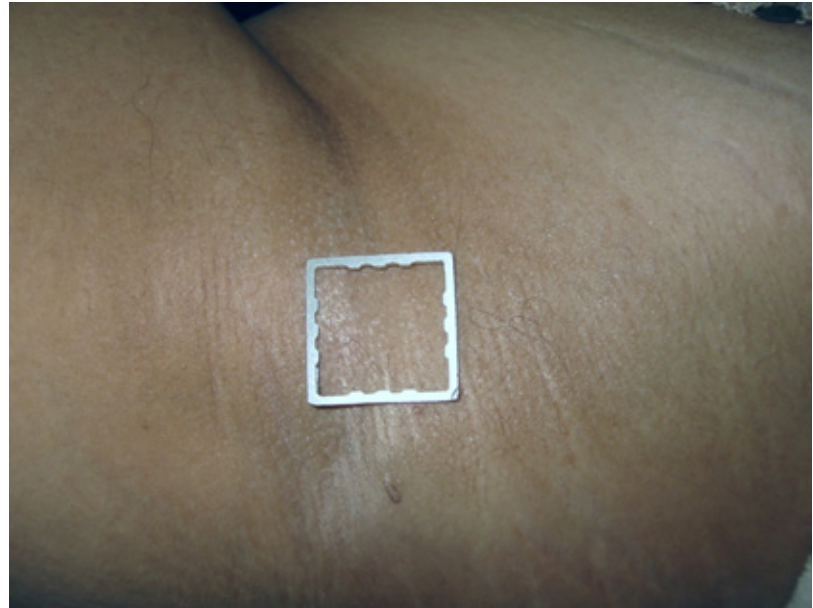
Result after 3 treatments

Removal of hair in axillae of a young female.
(Skin type IV)



Courtesy of Dr. Fauzia Khan

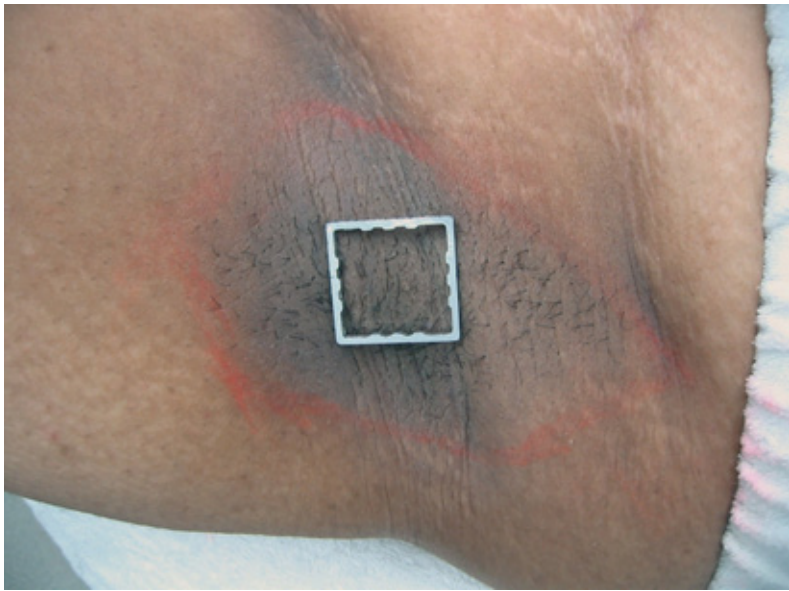
Before treatment



Courtesy of Dr. Fauzia Khan

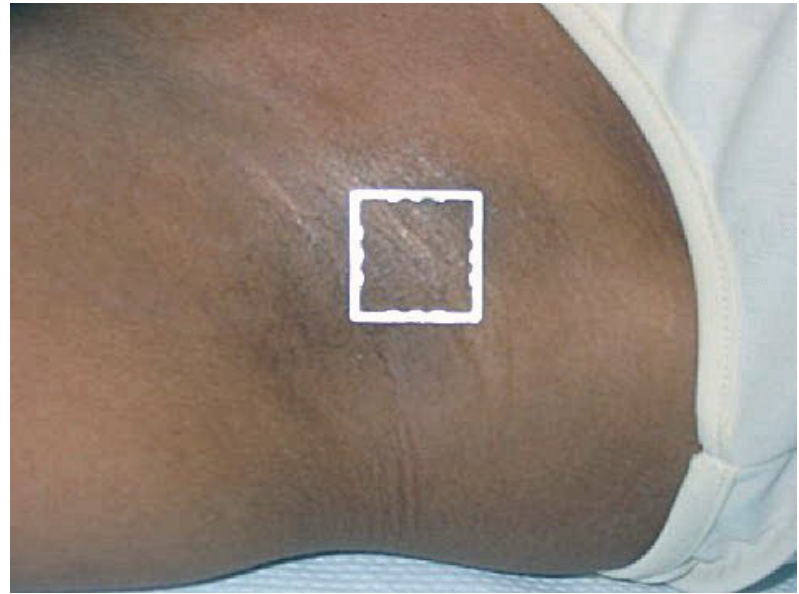
5 months after 5 treatments

Removal of hair in axillae of a young female.
(Skin type IV)



Courtesy of Dr. Fauzia Khan

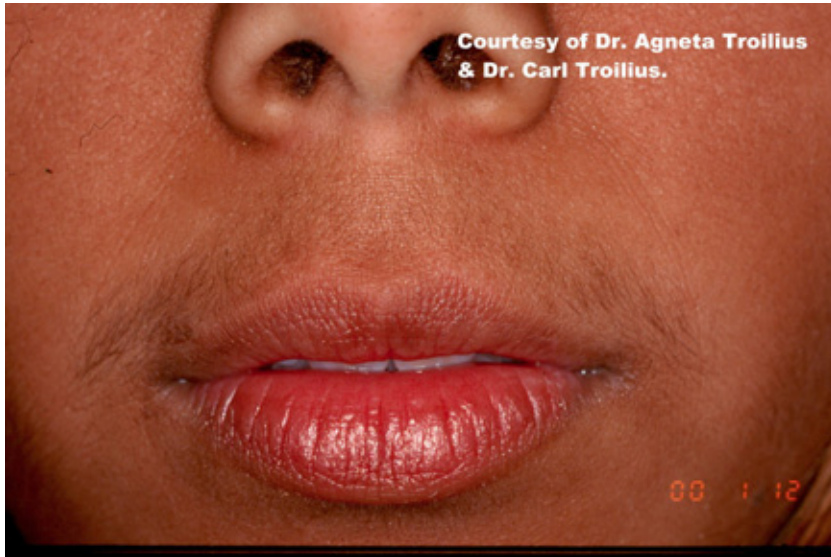
Before treatment



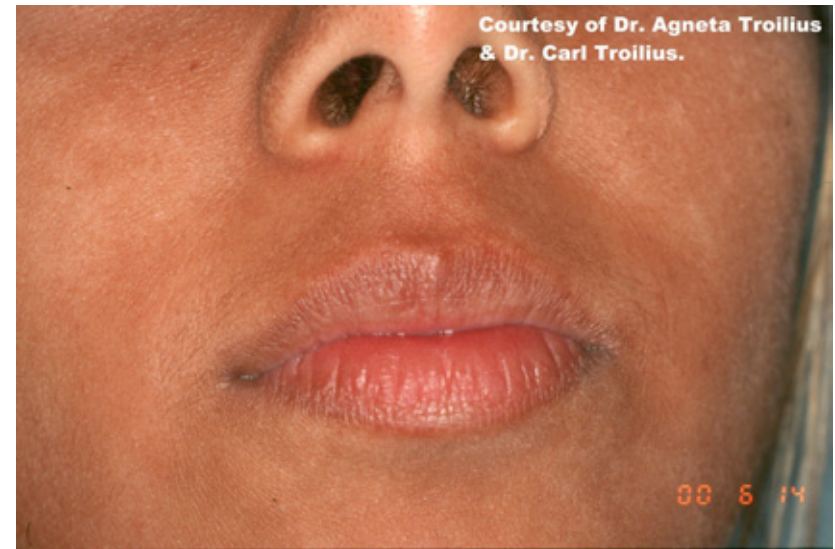Courtesy of Dr. Fauzia Khan

5 months after 5 treatments

Removal of hair on the upper lip of a young female
(Skin type 5)

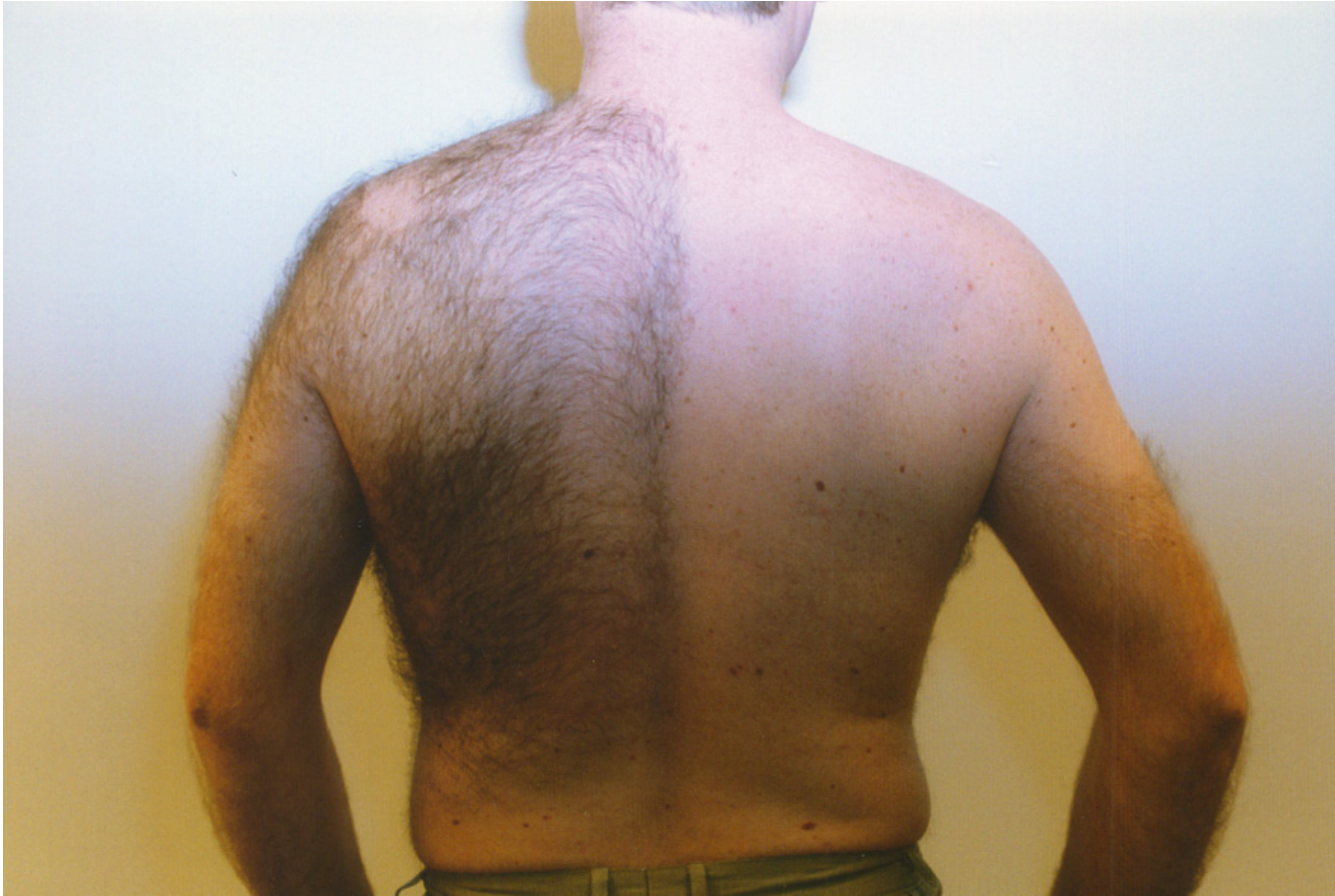

Before treatment



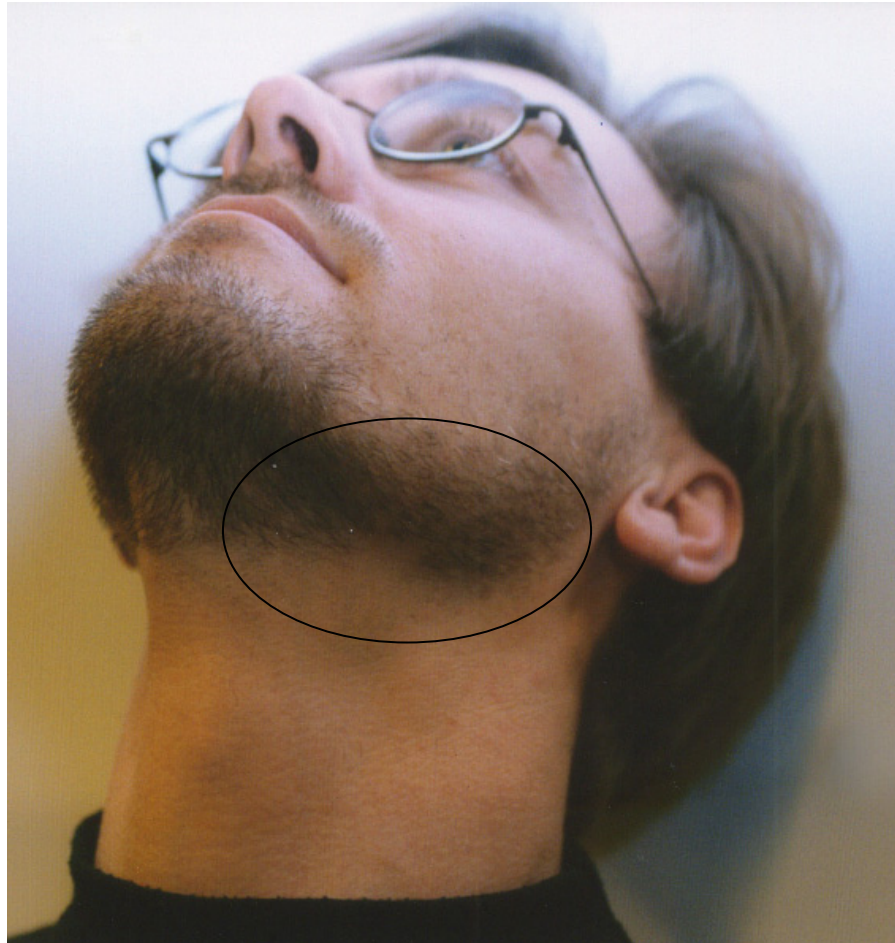Result after 4 treatments

Removal of hair on the back of a male



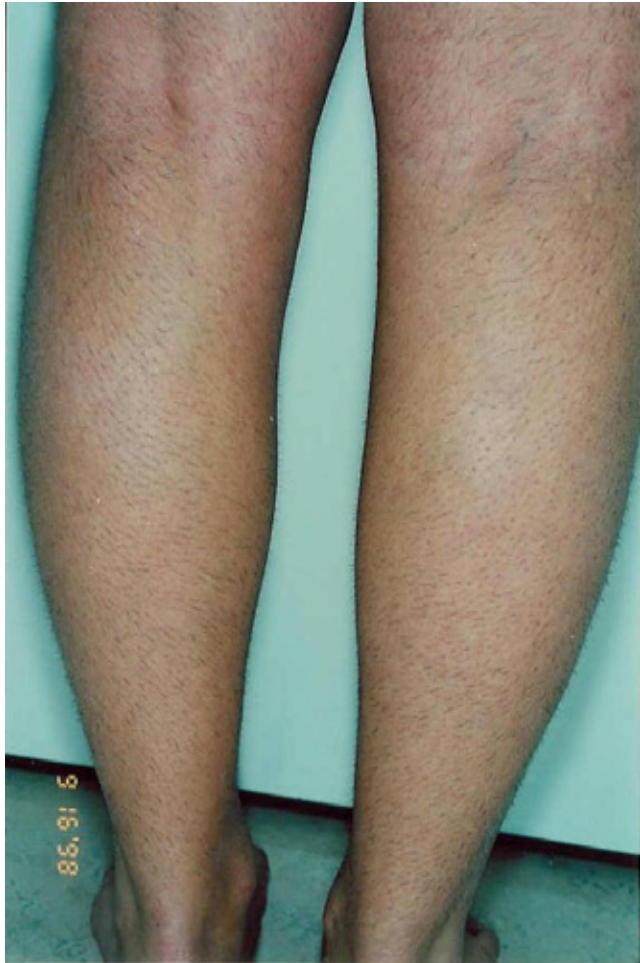Untreated area Result after 5 treatments

Removal of hair on the neck

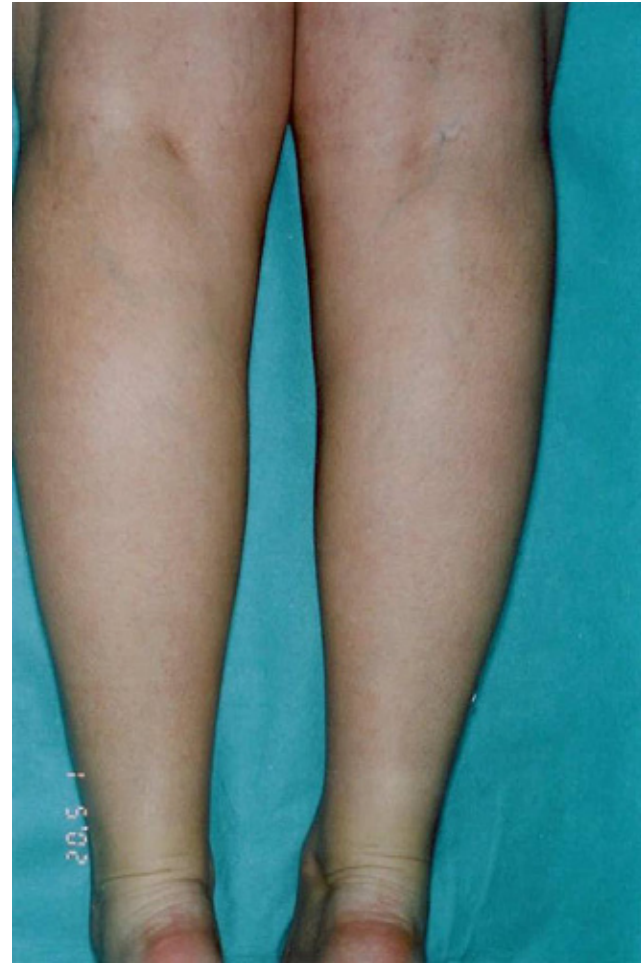

Result after 3 treatments

female patient suffering from Poly-cystic Ovary Syndrome

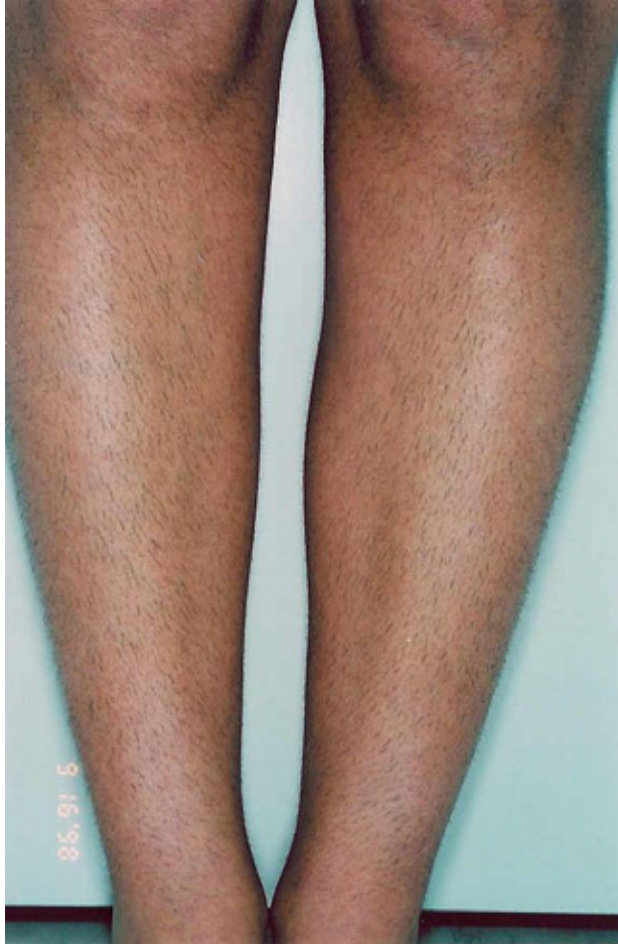

Before treatment

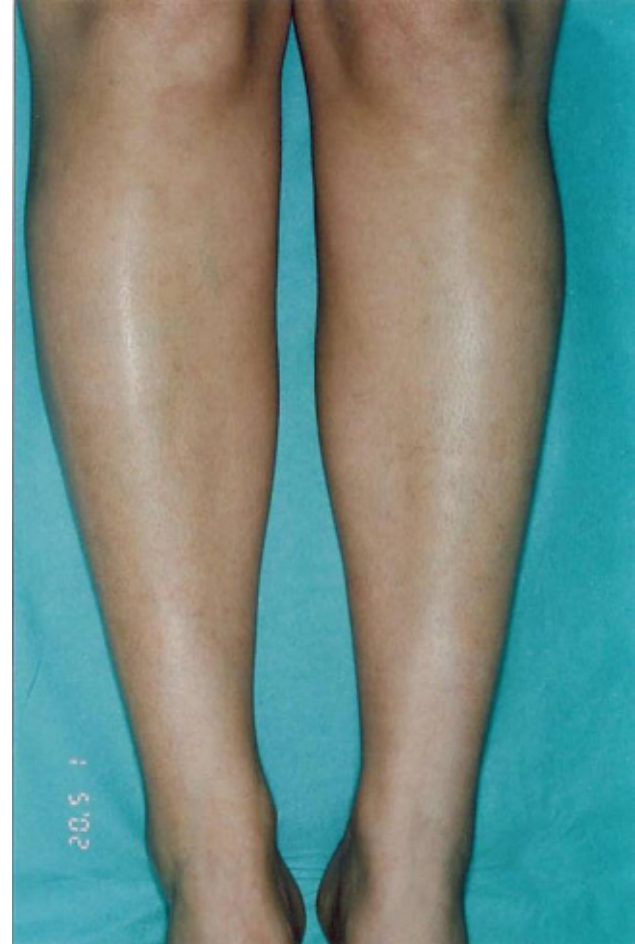

After several treatments

female patient suffering from Poly-cystic Ovary Syndrome

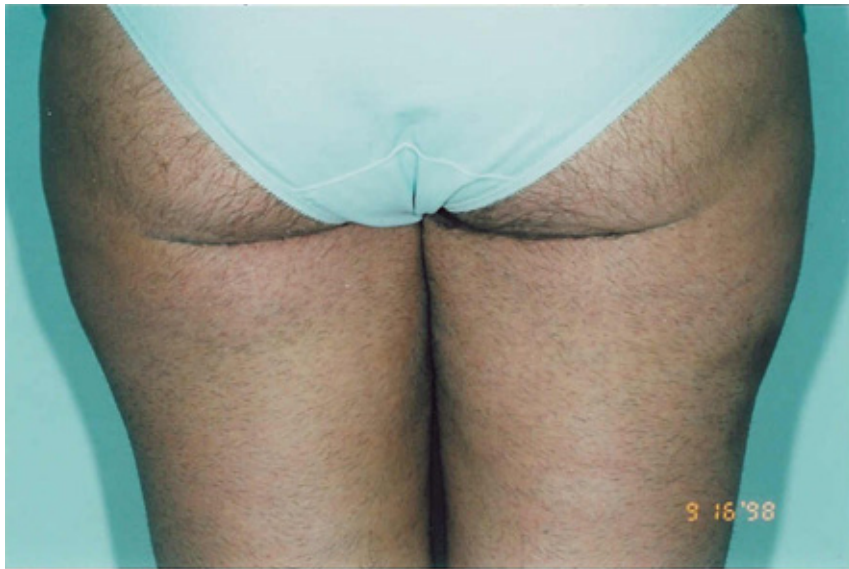

Before treatment

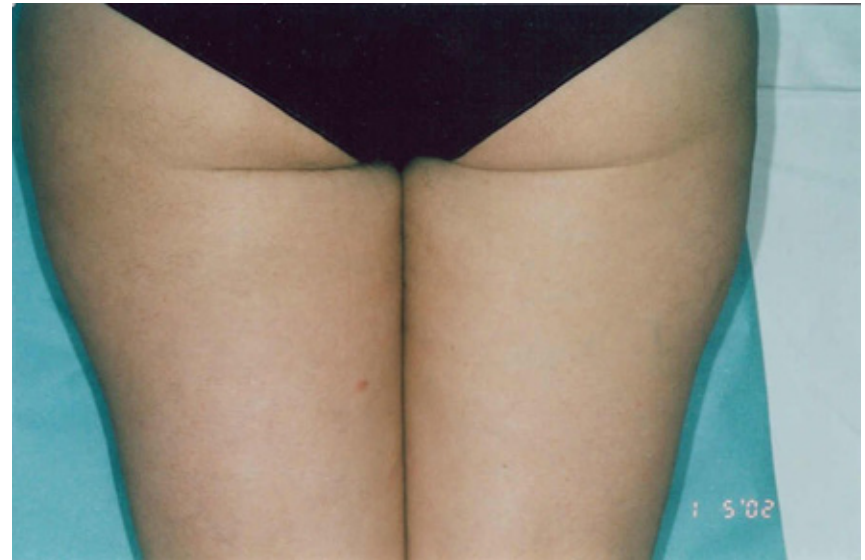

After several treatments

female patient suffering from Poly-cystic Ovary Syndrome



Before treatment



After several
treatments